

## Spondylolisthesis

***Spondylolisthesis occurs when one vertebra slips forward in relation to adjacent vertebrae. The condition can be a source of back pain, leg pain and other symptoms.***

### What Is Spondylolisthesis?

Spondylolisthesis occurs when one vertebra slips forward on the adjacent vertebrae. The condition may be congenital (hereditary), or the result of physical stresses on the spine or spinal degeneration. It may produce both a gradual deformity of the lower spine and a narrowing of the vertebral canal, and can cause back pain, leg pain and other symptoms.

**There are five types of spondylolisthesis\*:**



**Type I** is called dysplastic spondylolisthesis and is secondary to a congenital defect of either the superior sacral or inferior L5 facets or both with gradual slipping of the L5 vertebra.

**Type II**, isthmic or spondylolytic, in which the lesion is in the isthmus or pars interarticularis, has the greatest clinical importance in persons under the age of 50. If a defect in the pars interarticularis can be identified but no slipping has occurred, the condition is termed spondylolysis. If one vertebra has slipped forward on the other (horizontal translation), it is considered spondylolisthesis.

**Type II** can be divided into three subcategories:

**Type II A** is sometimes called Lytic or stress spondylolisthesis and is most likely caused by recurrent microfractures caused by hyperextension. It is also called a “stress fracture” of the *pars interarticularis* and is much more common in males.

**Type II B** probably also occurs from microfractures in the pars. However, in contrast to Type II A, the *pars interarticularis* remain intact but stretched out as the fractures fill in with new bone.

**Type II C** is very rare and is caused by an acute fracture of the pars. Nuclear imaging may be needed to establish a diagnosis.

**Type III** is a degenerative spondylolisthesis and occurs as a result of the degeneration of the lumbar facet joints. The alteration in these joints can allow forward or backward vertebral displacement. This type of spondylolisthesis is most often seen in older patients. In Type III, degenerative spondylolisthesis there is no pars defect and the vertebral slippage is never greater than 30%.

**Type IV**, traumatic spondylolisthesis, is associated with acute fracture of a posterior element (pedicle, lamina or facets) other than the pars interarticularis.

**Type V**, pathologic spondylolisthesis, occurs because of a structural weakness of the bone secondary to a disease process such as a tumor or other bone disorder.

## What Are The Symptoms Of Spondylolisthesis?

The most common symptom of spondylolisthesis is low back pain. Many times, a patient can develop the lesion (spondylolysis) between the ages of five and seven and not present symptoms until they are 35-years-old, when a sudden twisting or lifting motion will cause an acute episode of back and leg pain.

Usually the pain is relieved by extension of the spine and made worse when flexed. The degree of vertebral slippage does not directly correlate with the amount of pain a patient will experience. Fifty percent of patients with spondylolisthesis associate an injury with the onset of their symptoms.

In addition to back pain, patients may complain of leg pain. In this instance, there can be associated narrowing of the area where the nerves leave the spinal canal that produces irritation of a nerve root.

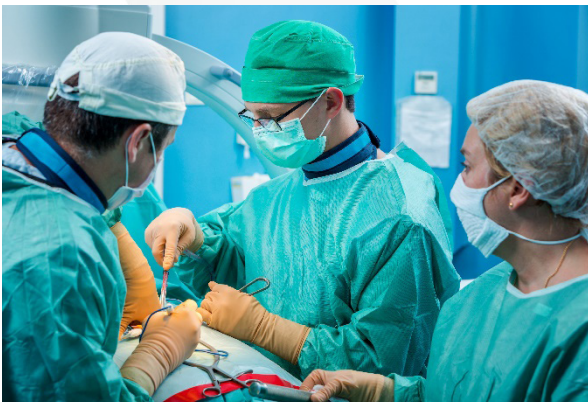
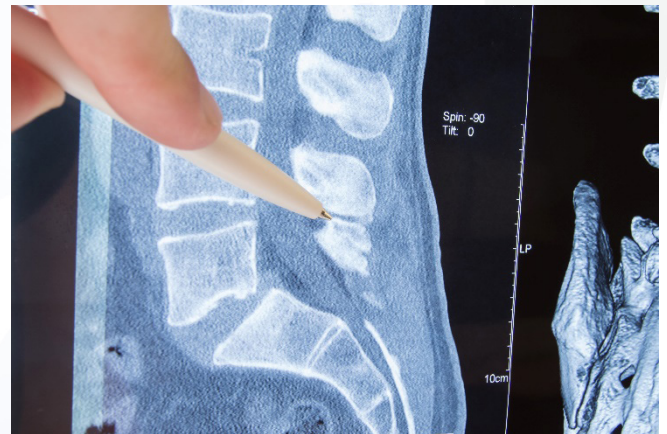
Many patients with spondylolisthesis will have vague symptoms and very little visible deformity. Often, the first physical sign of spondylolisthesis is tightness of the hamstring muscles in the legs. Only when the slip reaches more than 50 percent of the width of the vertebral body will there begin to be a visible deformity of the spine.

There may be a dimple at the site of the abnormality. Sometimes there are mild muscle spasms and usually some local tenderness can be felt in the area. Range of motion is often not affected, but some pain can be expected on hyperextension. Laboratory test results are normal in patients with one or both disorders.

## How Is Spondylolisthesis Diagnosed?

To determine if spondylolysis is the cause of your symptoms, your doctor may, in addition performing a physical exam, recommend a diagnostic test such as an x-ray, computed tomography (CT) scan or magnetic resonance imaging (MRI). The diagnosis of spondylolisthesis is confirmed by noting the forward position of one vertebral body on another.

A spondylolisthesis also is graded according to the amount that one vertebral body has slipped forward on another. A grade I slip means that the upper vertebra has slipped forward less than 25 percent of the total width of the vertebral body, a grade II slip is between 25 and 50 percent, a grade III slip between 50 and 75 percent, a grade IV slip is more than 75 percent, and in the case of a grade V slip, the upper vertebral body has slid all the way forward off the front of the lower vertebral body, a condition called spondyloptosis.



## How Is Spondylolisthesis Treated?

Your doctor will be able to discuss with you what your diagnosis means in terms of treatment options. For most people without any signs of nerve compression or other neurologic impairment, the first line of treatment consists of non-surgical therapies such as medication, rest and physical therapy. Bracing and epidural spinal injections also may be recommended.

Spine surgery is typically considered only after conservative therapies fail to adequately relieve symptoms over a significant period of time, or if evidence of nerve involvement, such as numbness or tingling, muscle weakness or bowel or bladder impairment, develops.

Surgical procedures that may be recommended for the treatment of spondylolisthesis include:

- Spinal decompression, a procedure in which bone is removed to eliminate nerve pressure
- Spinal fusion, a procedure in which bone graft material is placed between vertebrae to join – or fuse together – the vertebrae to restore spinal stability

The procedures are typically performed together as part of the same surgery, the overall goal of which is to stop the slippage, remove the source of irritation and inflammation and restore the stability of the spine.

The benefits of spine surgery, however, must be weighed against the risks. Discuss with your surgeon the risks and benefits of surgery, and the potential results of operative versus non-operative treatment.

\*Seimon, LP. Low Back Pain: Clinical Diagnosis and Management. Norwalk: Appleton-Century-Crofts, 1983.

Content provided by Medtronic.